Machine Translated by Google

Brazilian Scientific Journal of Health and Medicine (RBMED)
(Brazilian Scientific Journal of Health and Medicine) ISSN-e 3086-2477
Vol. 1, No. 1 | 2026

Peutz-Jeghers Syndrome and Malignant Transformation: A Case Report of Synchronous Gastric and Colorectal Adenocarcinoma

Peutz-Jeghers Syndrome and Malignant Transformation: Case Report of Synchronous Gastric and Colorectal Adenocarcinoma

Odair Machado Vaz
Giovana dos Santos Couto
Leandro Moraes Costa
Rubem Alves da Silva Neto
Rubem Alves da Silva Júnior

Federal University of Amazonas, Manaus-AM.
Getúlio Vargas University Hospital, Manaus-AM.

Summary

Introduction: Peutz-Jeghers Syndrome (PJS) is a rare autosomal dominant genetic disorder characterized by gastrointestinal hamartomatous polyps and characteristic mucocutaneous pigmentation.1 Case **Report:** A 63-year-old male patient, JKL, with a previous diagnosis of PJS, presented with progressive melena since December 2024, associated with severe anemia (hemoglobin 3 g/dL) and a weight loss of 7 kg in three months. Colonoscopy revealed colonic polyposis, with hamartomatous polyps with high-grade dysplasia in the cecum and sigmoid colon, as well as adenocarcinoma in the sigmoid colon. Upper digestive endoscopy demonstrated an ulcerated gastric lesion, and computed tomography showed synchronous gastric and colonic tumors. The patient underwent total gastrectomy and oncological rectosigmoidectomy, with satisfactory recovery after surgical re-intervention via evisceration. **Discussion:** Pilates syndrome (PS) confers a cumulative risk of neoplasia greater than 90% over a lifetime, requiring systematic endoscopic surveillance from adolescence onwards. This case illustrates the evolution of hamartomatous polyps to adenocarcinoma, reinforcing the need for screening and a multidisciplinary approach. **Conclusion:** Early and regular endoscopic surveillance is fundamental in PS for the timely detection and treatment of pre-malignant and malignant les
Keywords: Peutz-Jeghers Syndrome; Gastrointestinal Neoplasms; Adenocarcinoma; Hamartomatous Polyps; Endoscopic Surveillance.

Abstract

Introduction: Peutz-Jeghers Syndrome (PJS) is a rare genetic condition of autosomal dominant inheritance, characterized by gastrointestinal hamartomatous polyps and characteristic mucocutaneous pigmentation1. Case Report: A male patient, JKL, 63 years old, with a previous diagnosis of PJS, presented progressive melena since December 2024, associated with severe anemia (hemoglobin 3 g/dL) and weight loss of 7 kg in three months. Colonoscopy revealed colonic polyposis with hamartomatous polyps, high-grade dysplasia in the cecum and sigmoid colon, and adenocarcinoma in the sigmoid colon. Upper digestive endoscopy showed an ulcerated gastric lesion, and computed tomography showed a synchronous gastric and colonic tumor. The patient underwent total gastrectomy and rectosigmoidectomy, evolving satisfactorily after surgical reapproach by evisceration. Discussion: PJ confers a cumulative risk of neoplasia greater than 90% throughout life, requiring systematic endoscopic surveillance since adolescence. The case illustrates the evolution from hamartomatous polyps to adenocarcinoma, reinforcing the need for screening and a multidisciplinary approach. Conclusion: Early and regular endoscopic surveillance is essential in JTS for the timely detection and treatment of premalignant and malignant lesions.
Keywords: *Peutz-Jeghers syndrome; Gastrointestinal Neoplasms; Adenocarcinoma; Hamartomatous polyps; Endoscopic surveillance.*

Machine Translated by Google

Brazilian Scientific Journal of Health and Medicine (RBMED)
(Brazilian Scientific Journal of Health and Medicine) ISSN-e 3086-2477
Vol. 1, No. 1 | 2026

INTRODUCTION

Peutz-Jeghers syndrome (PJS) is a rare autosomal dominant disorder, with Estimated prevalence between 1:8,300 and 1:200,000 births, characterized by the classic triad: mucocutaneous melanocytic pigmentation, gastrointestinal hamartomatous polyps and predisposition to the development of neoplasms1 . The condition results from mutations in the gene. STK11 (also called LKB1), located on chromosome 19p13.3, which codes for a serine/threonine kinase involved in the regulation of cellular metabolism, polarity and proliferation2 .

Although hamartomatous polyps are classically considered benign lesions, Patients with SPJ have a cumulative cancer risk greater than 90% by age 701. The most frequent neoplasms include colorectal cancer (20-30%), gastric cancer (5-10%), pancreatic cancer (10-30%), breast cancer (45-50% in women), and genital tumors3,4. The transformation Malignant transformation of hamartomatous polyps, although uncommon, constitutes a recognized pathway of Carcinogenesis in this population. This report describes a case of SPJ that evolved into Synchronous colorectal adenocarcinoma, illustrating the importance of endoscopic surveillance. systematic and timely surgical approach.

CASE REPORT

Patient Presentation

Male patient, 63 years old, with a previous diagnosis of Peutz-Jeghers Syndrome, sought medical attention in December 2024 presenting with associated melena. The patient presented with asthenia, anemia, and a weight loss of 7 kg in three months. The patient reported a family history of the disease. Positive for SPJ in 2 siblings, both with irregular endoscopic follow-up.

Surgical History

In 1984, the patient underwent exploratory laparotomy due to pain. acute abdominal pain, without significant surgical findings. Due to the persistence of Regarding the symptoms, a new surgical approach was performed 20 days after the same hospitalization. revealing intestinal perforation, which culminated in segmental enterectomy with anastomosis. primary. Postoperative follow-up is unknown, although the patient reports having it, not detailed records are available.

Machine Translated by Google

Brazilian Scientific Journal of Health and Medicine (RBMED)
(Brazilian Scientific Journal of Health and Medicine) ISSN-e 3086-2477
Vol. 1, No. 1 | 2026

Current Medical History

In April 2025, the patient presented with gastrointestinal bleeding and episodes of syncope.
being admitted to the emergency room with severe anemia. Laboratory tests
They revealed a hemoglobin level of 3 g/dL, a hematocrit of 10%, and a mean corpuscular volume of 65 fL.
Serum ferritin of 5 ng/mL, characterizing severe iron deficiency anemia secondary to loss.
Chronic blood disorder. The patient underwent a blood transfusion to replace
Packed red blood cells and intravenous iron, resulting in improvement of the clinical picture.
being referred for imaging tests and upper digestive endoscopy and
low during the same hospitalization.

Endoscopic and Imaging Findings

The colonoscopy was performed as an emergency and revealed colonic polyposis.
Diffuse, with multiple hamartomatous polyps distributed throughout the colon. Biopsies of
Lesions in the cecum and sigmoid colon revealed high-grade dysplasia. Additionally,
A vegetating lesion was observed in the sigmoid colon, with suggestive endoscopic characteristics.
of malignancy (biopsy performed).

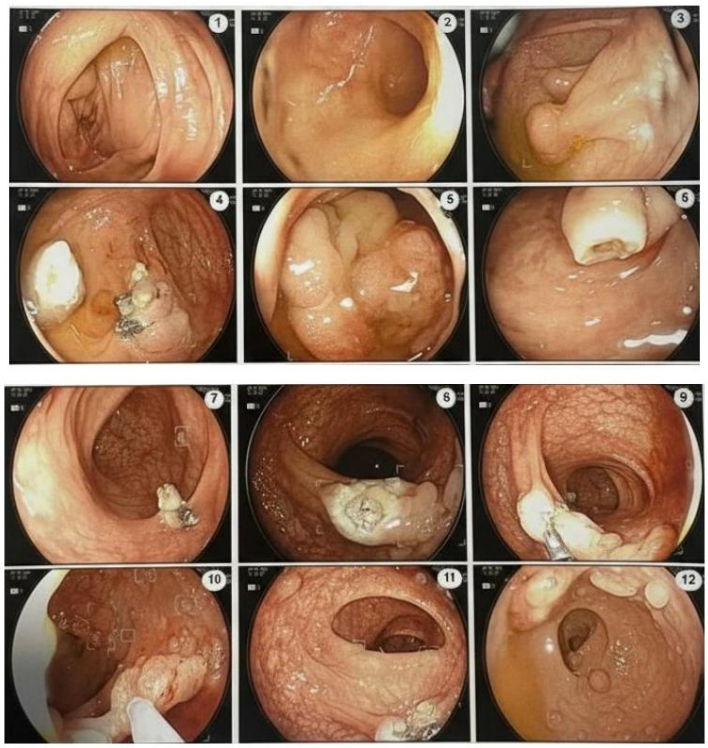

Machine Translated by Google

Brazilian Scientific Journal of Health and Medicine (RBMED)
(Brazilian Scientific Journal of Health and Medicine) ISSN-e 3086-2477
Vol. 1, No. 1 | 2026

The anatomopathological study of the colonic biopsy confirmed adenocarcinoma.
moderately differentiated in the sigmoid colon, with transitional areas between polyps
hamartomatous tumors with high-grade dysplasia and invasive adenocarcinoma.

Upper digestive endoscopy revealed an ulcerated lesion of approximately **3 cm** in the
Gastric body, with elevated borders and fibrinous base, whose biopsy demonstrated a process
Chronic inflammatory lesion with areas of intestinal metaplasia, with no signs of malignancy in the sample.
analyzed.

Abdominal computed tomography scan with intravenous contrast revealed
Focal gastric wall thickening and hypodense liver lesion in segment VI, suggesting
Synchronous gastric and colonic tumors, with possible liver metastasis.

Differential Diagnosis

The differential diagnosis included:
Familial adenomatous polyposis (FAP): ruled out by the presence of hamartomatous polyps and
characteristic mucocutaneous pigmentation.

- Cowden syndrome: ruled out due to the absence of cutaneous manifestations.
  characteristics and diagnostic criteria.
- Juvenile polyposis: differentiated by the histological pattern of the polyps and by the history.
  familiar.
- Sporadic colorectal cancer: less likely diagnosis given the syndromic context.

Conduct and Evolution

The patient underwent total gastrectomy with D2 lymphadenectomy and
Oncological rectosigmoidectomy with primary anastomosis. The procedure was performed without incident.
Intraoperative complications. On the seventh postoperative day, evisceration developed.
abdominal, undergoing surgical reintervention for resuturing of the abdominal wall with
Mass closure technique .

The postoperative recovery was satisfactory, with hospital discharge on the 11th postoperative day.
and currently remains under outpatient follow-up with a multidisciplinary team, including
Gastroenterology, clinical oncology, and digestive tract surgery.

Machine Translated by Google

Brazilian Scientific Journal of Health and Medicine (RBMED)
(Brazilian Scientific Journal of Health and Medicine) ISSN-e 3086-2477
Vol. 1, No. 1 | 2026

Definitive Anatomopathological Examination

The surgical specimen revealed:

- Sigmoid colon: Hyperplastic polyp. Absence of malignancy in the evaluated material.
- Stomach: Gastric adenocarcinoma, intestinal type, tubular, moderately differentiated. Going beyond the muscularis propria, without vascular or perineural invasion, with uncompromised surgical margins. 23 lymph nodes identified, of which 3 presented tumor involvement (pT3 pN2 pMx)

Immunohistochemical examination – Sigmoid colon

Adenocarcinoma with immunohistochemical results indicative of stability. microsatellite: MMR-PROFICIENT (MMR-P)

DISCUSSION

SPJ represents one of the hamartomatous polyposis syndromes with the greatest potential of malignancy, conferring a cumulative cancer risk estimated at 85-93% by age 70. age3,4. Malignant transformation follows the classic polyp-cancer sequence model, although the progression of hamartomatous polyps to adenocarcinoma can occur in a way more accelerated than that observed in sporadic adenomatous polyps.

In the case presented, the evolution of hamartomatous polyps with high-grade dysplasia. The presence of lesions in colon adenocarcinoma confirms the oncogenic potential of SPJ. Gastric ulcer and synchronous gastric-colonic tumor reinforce the need for investigation. Comprehensive in patients with SPJ, given the increased risk of neoplasms in multiple sites. anatomical5 .

A positive family history for SPJ in first-degree relatives is observed in approximately 50% of cases, which is consistent with the autosomal inheritance pattern. dominant. Identifying mutations in the STK11 gene allows for molecular diagnosis and genetic counseling for family members1,2 .

International guidelines recommend systematic endoscopic screening starting from adolescence or earlier, if symptomatic, including:

- Colonoscopy every 2-3 years.
- Upper digestive endoscopy every 2-3 years.

Machine Translated by Google

- Abdominal MRI or endoscopic ultrasound for evaluation.

  pancreatic.
- Annual mammograms starting at age 25 (for women).
- Annual gynecological ultrasound6 .

Surgical intervention is indicated for symptomatic polyps with a diameter greater than... 1.5 cm or with endoscopic features suggestive of malignancy. Enterectomies Segmental or colorectal resections may be necessary in cases of complications. (intussusception, bleeding, malignant transformation)7 .

This case illustrates the importance of rigorous endoscopic surveillance in patients with SPJ. allowing for the early detection of pre-malignant lesions and the timely treatment of neoplasms. The favorable outcome following extensive surgical intervention highlights the importance of certain procedures. multidisciplinary approaches in this high-risk population.

CONCLUSION

Peutz-Jeghers syndrome requires early and regular screening due to the high cumulative risk of malignancy1,2. This report demonstrates the evolution of polyps hamartomatous tumors for colorectal adenocarcinoma, reinforcing the need for surveillance. Systematic endoscopy since adolescence and timely surgical intervention. The history A positive family history reinforces the genetic component and the importance of genetic counseling. for family members. The favorable postoperative evolution highlights the importance of proper conduct. Multidisciplinary approaches in patients with SPJ.

REFERENCES

1. McGarrity TJ, Amos CI, Baker MJ. Peutz-Jeghers Syndrome. In: Adam MP, Everman DB, Mirzaa GM, et al., editors. GeneReviews® [Internet]. Seattle (WA): University of Washington, Seattle; 1999-2024. [cited 2025 Mar. 10]. Available at: https://www.ncbi.nlm.nih.gov/books/NBK1266/
2. Hearle N, Schumacher V, Menko FH, et al. Frequency and spectrum of cancers in the Peutz-Jeghers syndrome. Clin Cancer Res. 2006;12(10):3209-15. doi:10.1158/1078-0432.CCR-06-0083
3. Beggs AD, Latchford AR, Vasen HF, et al. Peutz-Jeghers syndrome: a systematic review and recommendations for management. Gut. 2010;59(7):975-86. doi:10.1136/gut.2009.198499
4. Van Lier MG, Westerman AM, Wagner A, et al. High cancer risk and increased mortality in patients with Peutz-Jeghers syndrome. Gut. 2011;60(2):141-7. doi:10.1136/gut.2010.223750

Machine Translated by Google

5. Giardiello FM, Trimbath JD. Peutz-Jeghers syndrome and management recommendations. Clin Gastroenterol Hepatol. 2006;4(4):408-15. doi:10.1016/j.cgh.2005.12.008
6. National Comprehensive Cancer Network. NCCN Clinical Practice Guidelines in Oncology: Genetic/Familial High-Risk Assessment: Colorectal. Version 2.2024.
7. Latchford AR, Phillips RKS. Peutz-Jeghers syndrome: the current management dilemmas. Tech Coloproctol. 2009;13(2):109-10. doi:10.1007/s10151-009-0481-8